

Case Study

Late onset anti-N-methyl-D-aspartate receptor encephalitis following Japanese encephalitis

Hnin Wint Wint Aung¹, Kyaw Linn¹, Aye Mya Min Aye¹, Chaw Su Hlaing¹, Aye Mu Saan¹, Khine Mi Mi Ko¹, Myo Thiri Swe¹, Cho Thair¹, Yi Yi Mar¹, Nway Nway¹, Phyu Phyu Myint¹, Ei Hnin Kyu¹, Haymar Han¹

ABSTRACT

Background: Recent studies have shown that autoimmune encephalitis such as anti- N-methyl-D-aspartate receptor (NMDAR) encephalitis can be triggered by infections such as herpes simplex. We report a child with Japanese encephalitis (JE) who developed relapsing neurological symptoms related to anti-NMDAR antibody.

Aim: The aim is to report another serious sequel of JE, which is one of the leading causes of viral encephalitis worldwide.

Case description: We report one pediatric case who developed worsening neurological symptoms of dystonia, sleep and behavioral problems and development of movement disorders and orofacial dyskinesia 8 weeks after confirmed JE. His serum and CSF were positive for anti-NMDAR antibody. His symptoms gradually improved after receiving immunotherapy.

Conclusion: Anti-NMDAR antibody testing is highly recommended in children with JE presenting with relapsing symptoms of movement disorders and/or behavioral problems.

Keywords: Japanese encephalitis, anti-NMDAR encephalitis, relapse, behavioral problems, movement disorders

Received on:

01-May-2018

Accepted for Publication:

23-Aug-2018

Correspondence to:

Hnin Wint Wint Aung
hninwintwint85@gmail.com

Author's Affiliation:

1. Pediatric Neurology Unit,
Yangon Children's Hospital,
Yangon, Myanmar

Introduction

Japanese encephalitis (JE), mosquito-borne flaviviral encephalitis, is one of the leading causes of viral encephalitis in eastern and southern Asia. It mostly affects children resulting in high risk of fatality and severe neurodisability¹. The patients with JE often have monophasic illness with acute onset and progressively deteriorating course. However, some patients with JE may have relapse after partial recovery, giving rise to the biphasic illness pattern².

Anti-N-methyl-D-aspartate receptor (NMDAR) encephalitis is the commonest autoimmune encephalitis among children and it is widely accepted that it can be triggered by herpes simplex virus³ and other viral infection such as Epstein-Barr virus, human herpes virus type 6 (HHV-6), cytomegalovirus, adenovirus or enterovirus⁴.

Two recent case reports described total four pediatric cases of anti-NMDAR antibody detected during relapsing phase of JE but could not determine whether JE normally triggers brain autoimmunity in the early stage of the illness or right before the relapsing stage^{5,6}. Here we report another pediatric case of JE who developed new neurological symptoms related to anti-NMDAR antibody during later course of monophasic illness.

Case Description

A previously well 7-year-old boy presented with 5 days of high fever and seizures. Seizures were focal onset and occurred 2-3 times/day from day 2 to day 4 of fever. Despite seizures were under control, he looked more encephalopathic and developed right-sided hemiparesis, right-sided upper motor neuron typed facial palsy, dystonia, irritability and sleep problems since day 10 of illness.

Lumbar puncture was done on day 9 of illness and CSF examination showed protein - 30 mg/dL, cells -15 per cumm with 100% lymphocytes. Bacteriological studies were negative. CSF JE Ig M antibody was positive. CT head showed small left thalamic infarct. He was discharged around 3 week of illness with slightly improved conscious level but dystonia and behavioral problems were left. Around 8 week time of illness, he came back with new movement disorders (stereotypic movements of rubbing of his face with his left hand and orofacial dyskinesia) and worsening of existing sleep problems, agitation, anger and dystonia which eventually led to testing of anti-NMDAR antibody.

CSF and serum samples were tested via indirect immunofluorescence method for anti-NMDAR antibody and both were positive. MRI scan revealed non-specific left thalamic hyperintensed signal in T2 and FLAIR sequences (Fig-1) which is similar to the finding of his previous CT scan. He was treated with intravenous methylprednisolone 30 mg/kg/day for 5 days followed by oral prednisolone (2mg/kg/day) for 6-8 week. His behavioral and sleep problems as well as right-sided hemiparesis and facial palsy resolved after 3 weeks of steroid treatment. When he went back home, independent ambulation and certain amount of expressive speech had regained with minimal residual orofacial dyskinesia.

Discussion

Our case is 5th pediatric case of post-JE anti-NMDAR antibody encephalitis. Although our patient had dystonia, sleep and behavioral problems since 2 week of illness, stereotypic movement and orofacial dyskinesia developed only after 8 weeks of illness. Because of limited in-house facility, anti-NMDAR antibody testing could be sent only when all

these symptoms appeared to fulfill the diagnostic criteria of anti-NMDAR encephalitis⁷.

There are two other previous case reports on anti-NMDAR encephalitis occurred as a relapsing phase of JE. One report from India is a 7-year-old boy who came back with predominant movement disorder after 25 days following his initial presentation and after significant recovery from JE. Both CSF and serum anti-NMDAR antibody were tested positive and responded well to immunotherapy⁵.

Another case study from China reported 3 pediatric cases (30 months, 14 years and 6 years of age respectively) in which new neurological symptoms developed between days 25 and 29 following first presentation. Anti-NMDAR IgG was detected in all 3 cases. All patients gradually improved with immunotherapy⁶.

In comparison with our case, clinical manifestations are more or less similar. However, there was no clear phase of recovery in our patient. Thus, we presumed our case had monophasic course, rather than biphasic or relapse, with relatively later development of features of immune encephalitis.

In our case, the possibility of recent JE reactivation was excluded by the presence of different movement disorders, sleep and psychiatric problems predominantly. Again, absence of new lesion in MRI brain and significant improvement following immunotherapy supported our diagnosis. But, we could not test for JE serology titer in Myanmar so that we don't have a way to prove it is not reactivation.

There are recent studies which point out viral brain infections are a cause for the

development of autoimmune encephalitis. In a retrospective review of 44 patients with HSVE, 30% of these patients developed antibodies against NMDAR³ whereby the three mechanisms have been proposed (1) molecular mimicry, (2) nonspecific B cell activation and (3) development of synaptic autoimmunity secondary to release of antigens by viral neuronal lysis⁸. Anti-NMDAR encephalitis has also been reported after other viruses such as VZV, EBV, HHV-6, CMV, adenovirus or enterovirus. Therefore, this phenomenon does not appear to be restricted to HSV^{4,9}. Similarly this mechanism could be applied to our case. However, further research is needed to confirm this hypothesis.

Conclusion

Anti-NMDAR encephalitis following JE in children has been increasingly reported. But there might still be many cases which are unrecognized or underdiagnosed. Like in our case with monophasic course and relatively later occurrence of symptoms, autoimmune encephalitis diagnosis can be missed without high index of suspicion. Thus we would like to highlight that testing for anti-NMDAR antibody in children with JE cases is critically important to serve immunotherapy regardless of phases of illness. It is also important to educate such a later onset of autoimmune symptoms can mimic relapsing or deteriorating stages of infectious encephalitis.

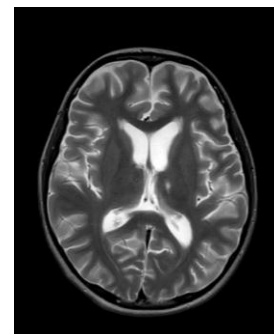


Fig: 1. MRI brain (Axial T2 W image) showing small hyperintense signal in left thalamus

Authorship: All the authors have contributed enough towards this publication to justify authorship criteria.

Copyright: We transfer all copyright ownership of the enclosed manuscript to the journal if it is accepted for publication.

Sources of support: The authors have no funding or conflicts of interest to disclose.

Consent and ethical approval: Written informed consent has been obtained from the parents to publish this case report.

References

1. Solomon T, Dung NM, Kneen R, et al. Japanese encephalitis. *J Neurol Neurosurg Psychiatry*. 2000; 68: 405–415.
2. Pradhan S, Gupta RK, Singh MB, et al. Biphasic illness pattern due to early relapse in Japanese-B virus encephalitis. *J Neurol Sci*. 2001; 183:13–18.
3. Pruss H, Finke C, Holtje M, et al. N-methyl-D-aspartate receptor antibodies in herpes simplex encephalitis. *Ann Neurol*. 2012; 72(6):902-911.
4. Pruss H. Postviral autoimmune encephalitis: manifestations in children and adults. *Curr Opin Neurol*. 2017; 30:000-000.
5. Pastel H, Chakrabarty B, Saini L, et al. A case of anti-N-methyl-D-Aspartate (NMDA) receptor encephalitis possibly triggered by an episode of Japanese B encephalitis. *Neurol India*. 2017; 65:895-7.
6. Ma J, Zhang T, Jiang L. Japanese encephalitis can trigger anti-N-methyl-D-aspartate receptor encephalitis. *J Neurol*. 2017; 264(6):1127-1131.
7. Graus F, Titulaer MJ, Balu R, et al. A clinical approach to diagnosis of autoimmune encephalitis. *Lancet Neurol*. 2016; 15:391–404.
8. Armangue T, Leypoldt F, Malaga I, et al. Herpes simplex virus encephalitis is a trigger of brain autoimmunity. *Ann Neurol*. 2014; 75(2): 317–323.
9. Schäbitz WR, Rogalewski A, Hagemester C, et al. VZV brainstem encephalitis triggers NMDA receptor immunoreaction. *Neurology*. 2014; 83:2309–2311